



Supernumerary breast in an adolescent girl

Maha Oudrhiri*; Houda Oubejja; Fouad Ettayebi; Hicham Zerhouni

Department of pediatric surgical emergencies of Rabat Children's Hospital, Faculty of Medicine and Pharmacy, Mohamed V University, Rabat, Morocco

***Corresponding Author(s): Maha Oudrhiri**

Pediatric surgical emergencies Department of Rabat Children's Hospital, Faculty of Medicine and Pharmacy of Rabat, S12A11 Hay Riad Rabat Morocco
Tel: +212-6616-545-15
Email: oudrhiri.md.phd@gmail.com

Received: Aug 26, 2019

Accepted: Oct 28, 2019

Published Online: Nov 01, 2019

Journal: Journal of Case Reports and Medical Images

Publisher: MedDocs Publishers LLC

Online edition: <http://meddocsonline.org/>

Copyright: © Oudrhiri M (2019). *This Article is distributed under the terms of Creative Commons Attribution 4.0 International License*

Clinical Image

Description

A 14-year-old girl presented to the surgical consultation room with brown skin lesion over the right scapula which enlarged in size and became deeper in color over the last year. There were no symptoms associated with this lesion and no similar case in the family.

On examination, she was asthenic girl in the III stage of puberty (Tanner classification). Under the right breast, she had a nipple and areola with a small part of glandular tissue.

A plastic surgery was proposed to the patient. The mother being not consenting, she refused the surgery.



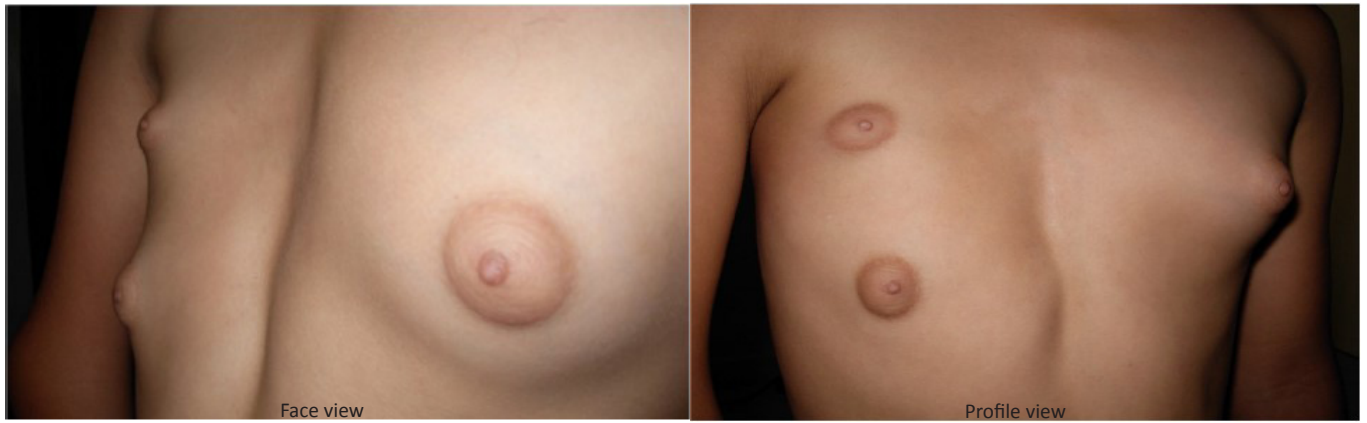


Figure 1: Unilateral supernumerary breast