



Dermoscopic of trichilemmal carcinoma

A Alaoui*; S Elloudi; M Bennani; Z Douhi; H Bay bay; FZ Mernissi

Departement of dermatology, CHU Hassan II, FES, Morocco

***Corresponding Author(s): El Harrouni Alaoui**

Departement of dermatology, CHU Hassan II, FES,
Morocco

Email: ealaouiaicha@gmail.com

Received: Aug 07, 2019

Accepted: Sep 09, 2019

Published Online: Sep 11, 2019

Journal: Journal of Case Reports and Medical Images

Publisher: MedDocs Publishers LLC

Online edition: <http://meddocsonline.org/>

Copyright: © A Alaoui (2019). *This Article is distributed under the terms of Creative Commons Attribution 4.0 International License*

Keywords: Trichilemmal carcinoma; Malignant tumors

Clinical Image

Description

Trichilemmal carcinoma (TC) is a rare malignant adnexal neoplasm with outer roots heath differentiation was first described by Headington. TC is commonly located on the scalp, forehead and neck, trunk or the upper extremities. Nevertheless an adverse outcome may occur with ganglion metastases and rarely haematogenous. Differential diagnosis is very important to distinguish it from the other malignant tumors, Although dermoscopic examination is very important to perform while considering the differential diagnosis of skin cancers, it is sometimes difficult to distinguish adnexal tumors from non melanoma skin cancers as in our case. We report a case of trichilemmal carcinoma in the inguinal region, which might have been diagnosed as a squamous cell carcinoma but Dermoscopic view of the tumor suggested a trichilemmal carcinoma, confirmed by histopathological examination.



Cite this article: Alaoui A, Elloudi S, Bennani M, Douhi Z, Baybay H, et al. Dermoscopic of trichilemmal carcinoma. Case Rep Clin Images. 2019; 2(1): 1023.

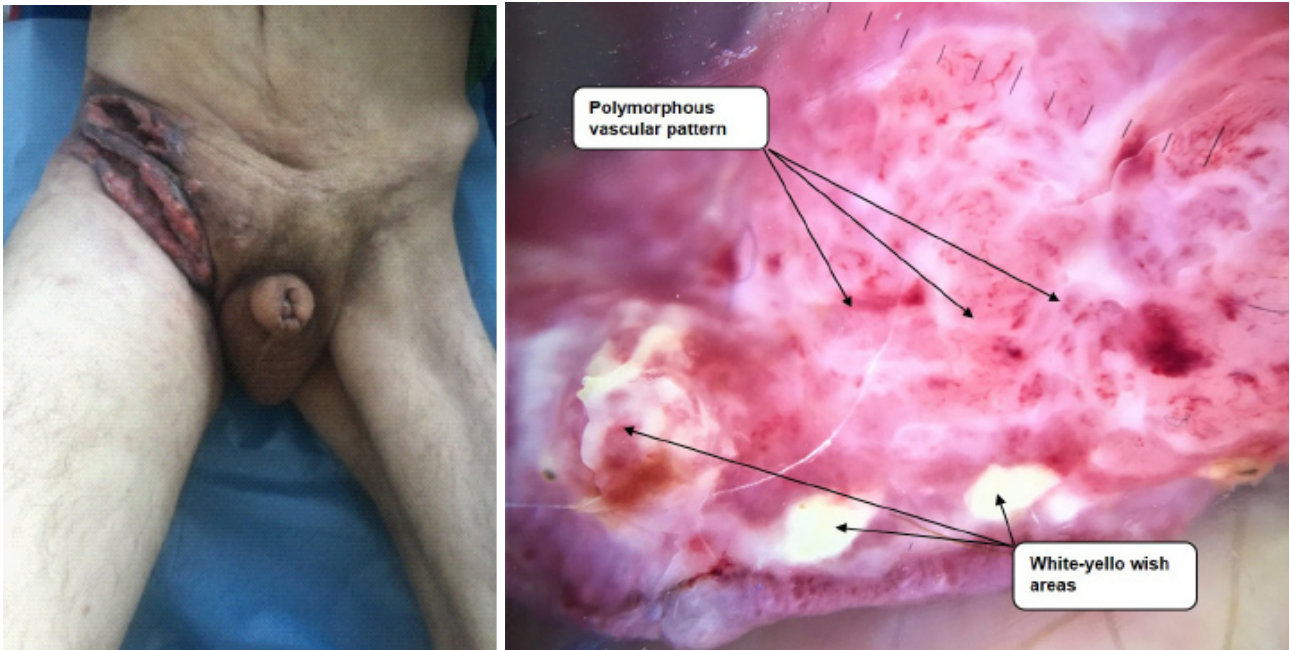


Figure 1: Dermoscopy aspect: Polymorphous vascular pattern, White-yellowish areas, and Ulceration

References

1. Reis JP, Tellechea O, Cunha MF, Baptista AP. Trichilemmal carcinoma: Review of 8 cases. *J Cutan Pathol.* 1993; 20: 44-49.
2. Lallas A, Moscarella E, Argenziano G, Longo C, Apalla Z, et al. Dermoscopy of uncommon skin tumours. *Australas J Dermatol.* 2014; 55: 53-62.
3. Arslan Z, Bali Z, Evrenos M, Temiz P, Ermertcan A. Dermoscopic features of trichilemmal carcinoma. *Indian journal of dermatology. J Dermatol Venereol Leprol.* 2019; 85: 321-323.