



Chronic Sinus Tract Formation Following Intramuscular Vaccination in an Infant: A Case Report

Varsha Kotte¹; Manasa Reddy Vadhi^{1*}; Shasanka Shekhar Panda¹; Shrinivas B Somalwar²; Shoorashetty Manohar Rudresh³

¹Department of Pediatric Surgery, AIIMS Bibinagar, Hyderabad.

²Department of Pathology, AIIMS Bibinagar, Hyderabad.

³Department of Microbiology, AIIMS Bibinagar, Hyderabad.

***Corresponding Author(s): Manasa Reddy Vadhi**

Assistant Professor, Department of Pediatric Surgery AIIMS, Bibinagar, Hyderabad, India.

Tel: 8427692770; Email: docmanasareddy@gmail.com

Abstract

Chronic sinus tract formation at a vaccination site is an exceptionally rare adverse event following immunization. In tuberculosis-endemic regions, such lesions may mimic mycobacterial infection leading to diagnostic uncertainty. We report an 11-month boy with a persistent discharging sinus over the left thigh, appearing months after routine 14-week vaccinations. An initial painless swelling noted one-week post-vaccination subsided with conservative management but recurred and ruptured, resulting in persistent discharge. Imaging revealed a 2-cm blind-ending subcutaneous tract, which was completely excised. Histopathology showed chronic granulomatous inflammation, while special stains and molecular testing (GeneXpert MTB/RIF) were negative for *Mycobacterium tuberculosis* suggesting a sterile inflammatory reaction. This case highlights a rare post-vaccination complication that may mimic infection. Early recognition can prevent unnecessary therapy, and surgical excision provides definitive treatment.

Received: Apr 28, 2026

Accepted: May 14, 2026

Published Online: May 21, 2026

Journal: Journal of Case Reports and Medical Images

Publisher: MedDocs Publishers LLC

Online edition: <http://meddocsonline.org/>

Copyright: © Manasa Reddy V (2026). *This Article is distributed under the terms of Creative Commons Attribution 4.0 International License*

Keywords: Granulomatous Inflammation; Aluminium Adjuvant; Injection Site Reaction; Surgical Excision; Case Report.

Introduction

Adverse Events Following Immunization (AEFI) are common in pediatric practice but are localized, transient, and self-limiting. Injection site abscesses and nodules are commonly reported after aluminium-adsorbed vaccines [1]. However, development of a chronic, discharging sinus tract at the site of a routine intramuscular (IM) injection site is exceedingly rare. In tuberculosis-endemic regions like India, chronic granulomatous lesions often raise suspicion of tuberculous abscess or atypical mycobacterial infection, leading to diagnostic uncertainty [2]. Differentiating between an indolent infectious process and a sterile, adjuvant-induced inflammatory reaction is essential to avoid unnecessary antimicrobial or anti-tubercular therapy. We report an unusual case of chronic sinus tract formation at an intramuscular vaccination site. The case report has been reported in line with the Scare checklist [3].

Case Report

An 11-month boy was brought with persistent discharging sinus over mid-anterolateral aspect of the left thigh. His parents noticed a localized swelling one week after he received 14-week intramuscular vaccination (DPT, Hepatitis B, Hib) at that site. It was initially painless, without fever or redness and subsided with conservative management.

At 10 months of age, the swelling reappeared and gradually increased in size before spontaneous rupture with intermittent serous discharge. He remained afebrile and systemically well. Examination confirmed a single sinus opening over the mid-anterolateral aspect of the left thigh with minimal serous discharge and no erythema, induration, or inguinal lymphadenopathy (Figure 1a).



Cite this article: Varsha K, Manasa Reddy V, Shasanka Shekhar P, Somalwar SB, Shoorashetty MR, et al. Chronic Sinus Tract Formation Following Intramuscular Vaccination in an Infant: A Case Report. *J Case Rep Clin Images*. 2026; 8(1): 1174.

X-ray didn't show osteomyelitis. Ultrasonography (USG) demonstrated a blind-ending sinus tract in the subcutaneous plane approximately 2 cm in length with minor ramifications but no intra-muscular extension. The chronic non-healing nature of the sinus necessitated surgery. Through an elliptical incision, a fibrotic, blind-ending tract extending to the deep fascia overlying the vastus lateralis was excised (Figure 1b). Histopathology revealed chronic granulomatous inflammation characterized by epithelioid cells (Figure 1c, d). Ziehl Neelson (ZN) staining, molecular testing (GeneXpert MTB/RIF and PCR for non-tuberculous mycobacteria) and Lowenstein-Jensen culture showed no evidence of *Mycobacterium tuberculosis* or Non-Tuberculous Mycobacteria (NTM). The patient recovered with no recurrence at three months of follow-up.

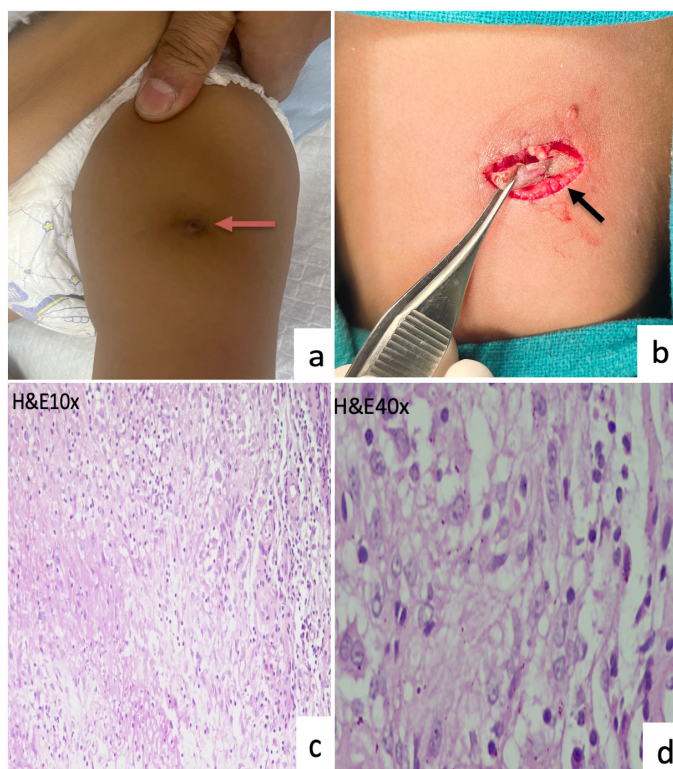


Figure 1: (1a) Clinical image of the left thigh of the infant showing sinus opening in the antero-lateral aspect of the thigh (red arrow). (1b) Intra-operative image showing an elliptical incision around the opening (black arrow). (1c&d) Haematoxylin and Eosin (H&E) staining images from the sinus tract tissue show ill-formed granuloma comprised of epithelioid cells, foamy histiocytes occasional binucleated histiocytes and chronic inflammatory cell collections of lymphocytes and plasma cells.

Discussion

The intramuscular route is the preferred route for most vaccines as rich vascular supply maintains immunogenicity of the vaccine and minimises local tissue reactions [4]. Nevertheless, local complications range from injection site pain, irritation, local induration to sterile abscess and granuloma formation.

Adverse reactions may result from local tissue trauma or immunologic responses to constituents, particularly aluminium adjuvants, which enhance immunogenicity in DTaP-containing preparations [5]. However, inadvertent deposition in the subcutaneous tissue can cause delayed hypersensitivity reaction resulting in persistent nodules, sterile abscesses, or granulomatous inflammation. Such reactions are likely with improper injection technique, inadequate needle length, or relatively small muscle mass in infants [6].

The clinical course in our patient is consistent with the delayed inflammatory pattern described in aluminium-adjuvant associated granulomas. They typically present as persistent nodules, occasionally form sterile abscesses [7]. However, progression to a chronic epithelialized sinus tract is unusual and a secondary structural complication due to chronic inflammation and fibrosis.

In tuberculosis-endemic regions, a chronic discharging sinus with granulomatous histology poses a diagnostic challenge, leading to empirical anti-tubercular therapy. In the present case, the absence of systemic features, lack of caseation, and negative microbiological and molecular tests helped exclude an infective etiology.

While sterile vaccine-related granulomas usually respond to topical corticosteroids, a persistent sinus tract necessitates surgery. Complete excision of the tract removes the nidus and provides definitive treatment.

To the best of our knowledge, chronic sinus tract formation following routine intramuscular vaccination has not been previously reported in the literature, making this an unusual presentation of a localised post-vaccination inflammatory reaction. Awareness of this entity is important to avoid diagnostic confusion and unnecessary antimicrobial therapy.

Author Contributions: Varsha Kotte- Original draft preparation, Conceptualisation; Vadhi Manasa reddy- Editing, reviewing, Conceptualisation; Shasanka Shekhar Panda- Supervision; Shrinivas B. Somalwar- Supervision; Shoorashetty Manohar Rudresh- Supervision.

Statements and Declarations: None.

Ethical Considerations: Our institution does not require ethical approval for reporting individual cases or case.

Consent to Participate: Written informed consent was obtained from the parent for the publication.

Consent for Publication: Written informed consent was obtained from the parent for the publication.

Declaration of Conflicting Interests: The author(s) declared no potential conflicts of interest with respect to the research, authorship, and/or publication of this article.

Data Availability: Data is available with the corresponding author who can be contacted for further details.

References

- Vargas KM, Koil A, Dehority W. Recurrent Sterile Abscesses After Immunization with Aluminium-Adjuvant Based Vaccines. *Clin Paediatric (Phila)*. 2018; 57(6): 733-737.
- Prasad A, Kumar P, Patra P, Prasad A. Tubercular Abscess near Diphtheria-Pertussis-Tetanus Injection Site: A Rare Complication of Immunization. *Indian J Community Med*. 2019; 44(1): 64-65.
- Agha RA, Franchi T, Sohrabi C, Mathew G, Kerwan A. SCARE Group. The SCARE 2020 Guideline: Updating Consensus Surgical Case Report (SCARE) Guidelines. *Int J Surg*. 2020: 1743-9191(20)30771-8.
- Nakajima Y, Fujii T, Mukai K, Ishida A, Kato M, et al. Anatomically safe sites for intramuscular injections: A cross-sectional study on young adults and cadavers with a focus on the thigh. *Hum Vaccine Immunotherapy*. 2020; 16(1): 189-196

5. Jackson LA, Peterson D, Nelson JC, Marcy SM, Naleway AL, et al. Vaccination site and risk of local reactions in children 1 through 6 years of age. *Paediatrics*. 2013; 131(2): 283-9.
6. Rustemeyer T, van Hoogstraten IMW, von Blomberg BME, Scheper RJ. Mechanisms of allergic contact dermatitis. In: Johansen JD, Mahler V, Lepoittevin JP, Frosch PJ, editors. *Kuneva's Occupational Dermatology*. 3rd ed. Cham: Springer International Publishing. 2020: 153-168.
7. Trollfors B. Itching nodules and aluminium allergy following vaccination with aluminium-adsorbed vaccines-Not a negligible problem. *Acta Paediatric*. 2020; 109(12): 2444-2445.