



# Double Chambered Right Ventricle with an Intact Interventricular Septum: A Case Report with Literature Review

Sarsari Mohamed<sup>1,2\*</sup>; Abbi Souad<sup>1,2</sup>; Krimech Amine<sup>1,2</sup>; Faraj Raid<sup>1,2</sup>; Kerrouani Oualid<sup>1,2</sup>; Zarzur Jamila<sup>1,2</sup>; Amri Rachida<sup>1,2</sup>; Cherti Mohamed<sup>1,2</sup>

<sup>1</sup>Mohammed V university, Rabat, Morocco.

<sup>2</sup>Cardiology B Department, Ibn Sina university Hospital center, Morocco.

## \*Corresponding Author(s): Sarsari Mohamed

Cardiology B Department, Ibn Sina university Hospital center, Morocco.

Tel: +212-658372068; Email: med.sar95@gmail.com

Received: Dec 18, 2024

Accepted: Jan 02, 2025

Published Online: Jan 09, 2025

Journal: Annals of Cardiology Case Reports

Publisher: MedDocs Publishers LLC

Online edition: <http://meddocsonline.org/>

Copyright: © Mohamed S (2025). *This Article is distributed under the terms of Creative Commons Attribution 4.0 International License*

**Keywords:** Double chambered right ventricle; Mid-ventricular stenosis; Intact interventricular septum; Right ventricular cardiomyopathy; Adult congenital heart disease.

**Abbreviation:** RV: Right Ventricle; DCRV: Double Chambered Right Ventricle; LV: Left Ventricle; RVP: Right Ventricular Pressure.

## Introduction

Double chambered right ventricle(DCRV) is a rare congenital heart disease, characterized by the presence of an abnormal muscle band dividing the right ventricle into two chambers proximal and distal [1]. DCRV is associated in most cases with other congenital malformations [3,7]. Treatment is surgical with an excellent long-term prognosis [8].

## Case presentation

The patient was 68 years old, without any particular history and had been suffering from exertional dyspnea for five years

## Abstract

Double Chambered Right Ventricle (DCRV) is a rare congenital heart disease, characterized by the presence of an abnormal muscle band dividing the right ventricle into two chambers proximal and distal, most cases are diagnosed in childhood or adolescence, rarely in adulthood. Clinical symptomatology is varied and depends on the extent of intraventricular obstruction. DCRV is associated in 80 to 90% of cases with other congenital malformations. Treatment is surgical with an excellent long-term prognosis.

We report in this work the observation of a 68 year old patient, presenting since five years a dyspnea of effort with progressive aggravation and whose etiological assessment revealed a mid-ventricular stenosis of the right ventricle isolated, without other associated anomalies, the patient was referred to cardiovascular surgery for further management.

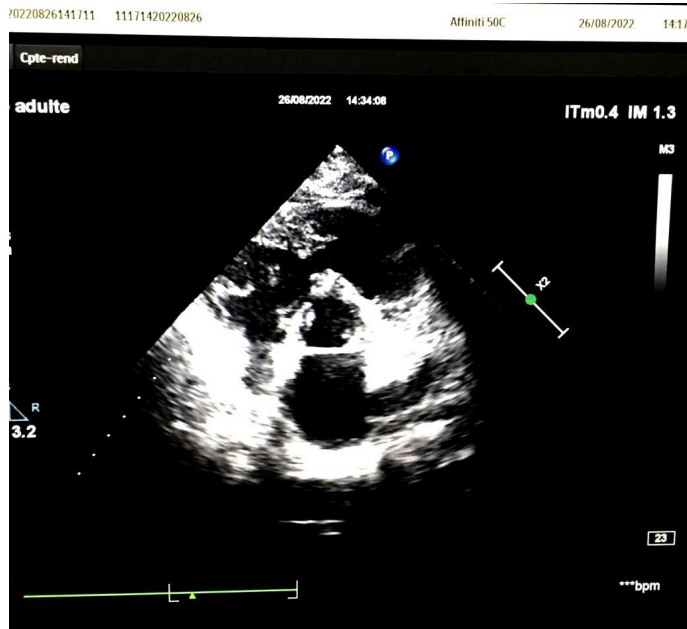
This case is of particular interest, on the one hand because there are very few cases described in the literature where the diagnosis was made at a very late age, and on the other hand because midventricular stenosis of the RV is rare and even rarer when the interventricular septum is intact.

which had increased two weeks before her admission. The clinical examination revealed a regular rhythm, a harsh systolic murmur at the pulmonary focus 5/6 of intensity, maximum in the left parasternal and radiating on all the precordium, the B2 was preserved, there was no sign of heart failure. The electrocardiogram was in sinus rhythm with a heart rate at 60cpm, there were also signs of right-sided cavitory overload. The chest X-ray showed a normal-sized cardiac silhouette with moderate pulmonary hypovascularization. Doppler echocardiography (Figure 1, Figure 2, Figure 3, Figure 4, Figure 5) showed a right intraventricular muscle band responsible for partitioning of the right ventricle into two chambers with elevated right ventricu-

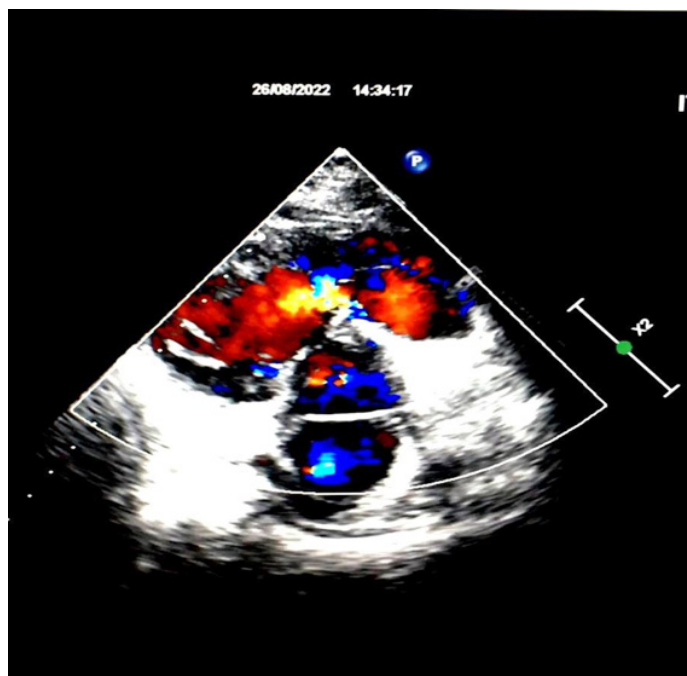


**Cite this article:** Mohamed S, Amine K, Souad A, Raid F, Oualid K, et al. Double Chambered Right Ventricle with an Intact Interventricular Septum: A Case Report with Literature Review. *Ann Cardiol Case Rep.* 2025; 5(1) : 1010.

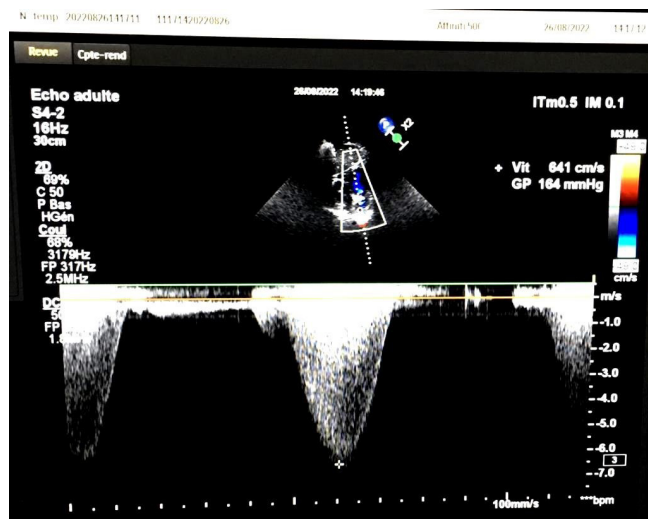
lar pressure in the upstream chamber, estimated in continuous Doppler at 160 mmHg peak. The Right Ventricular Pressure (RVP) assessed on tricuspid insufficiency flow was isosystemic and estimated at 140 mmHg. The right ventricle was not dilated and slightly hypertrophied with good contractility. The pulmonary pathway was normal. The septal curvature was flattened. There was no intraventricular communication or other anomalies. The patient was then referred to cardiovascular surgery for further management.



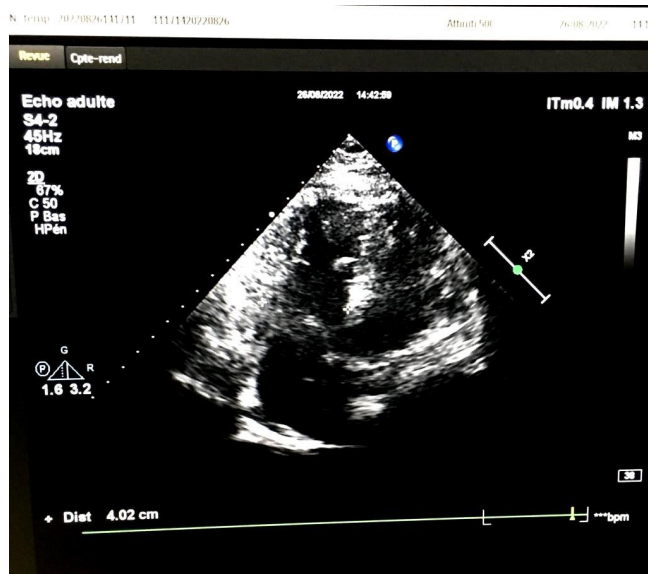
**Figure 1:** Echocardiography, parasternal short axis, 2D incidence showing mid-ventricular stenosis of the RV with a letter eight aspect.



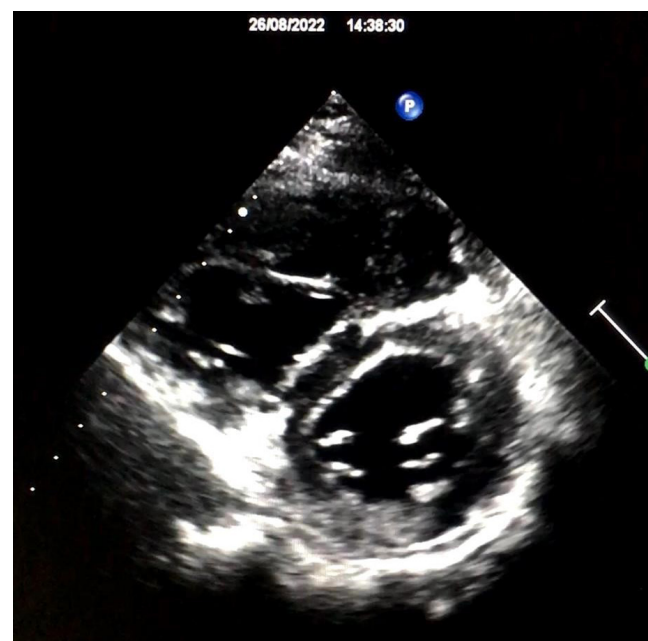**Figure 2:** Echocardiography, incidence parasternal short-axis, color doppler with aliasing indicating intra-RV obstruction.



**Figure 3:** Echocardiography, pressure in the upstream chamber, estimated in continuous doppler at 160 mmHg peak.



**Figure 4:** Echocardiography, apical incidence, right ventricle is non-dilated and slightly hypertrophied.



**Figure 5:** Echocardiography, transmitral incidence showing a flattened septal curvature.

## Discussion

Double chamber right ventricle (DCRV) is a congenital heart disease characterized by the presence of an abnormal muscle band dividing the right ventricle into two chambers (a proximal high pressure chamber and a distal low pressure chamber) [1]. Its incidence varies between 0.5 and 2% [2]. The diagnosis is most often made in early childhood and sometimes in adolescence between 4 months and 20 years of age [1], rarely asymptomatic or undiagnosed cases may reveal themselves in adulthood [1-4]. In our patient the diagnosis was made at the age of 68 years, she remained asymptomatic for a long period of time which makes this clinical presentation a unique and very valuable case.

In the literature, patients were often asymptomatic and referred in most cases for evaluation of a murmur. In a study of 52 patients, Cil et al [1] reported 40% asymptomatic patients, 35% patients with asthenia, 17% with exertional dyspnea, while heart failure, cyanosis and palpitations were present in 10 to 12% of cases. Syncope, vertigo, chest pain and infective endocarditis are reported by other authors as a mode of presentation of DCRV in adults [5]. Our patient presented with exertional dyspnea with asthenia evolving for almost five years. She never had syncope or lipothymia even if the right intraventricular obstruction seems to be very important with an isosystemic RVP, the patient risks at any moment to syncope and to have a cardiocirculatory arrest.

DCRV is associated in 80 to 90% of cases with other congenital anomalies [6], the Ventricular Septal Defect (VSD) is the most frequent [3,7]. Other malformations described in the literature are: subaortic stenosis, pulmonary valve stenosis, tetralogy of Fallot, pulmonary venous return anomalies and transposition of the great vessels. Our patient presented an isolated form of DCRV as some series reported in the literature [8]. The frequency of associated cardiac malformations, incite to systematically search them before any diagnosis of DCRV.

Echocardiography is the *first-line test* for the diagnosis of DCRV, as in our patient's case.

Transesophageal echocardiography, magnetic resonance imaging, and cardiac catheterization may be considered as a second line in situations where the diagnosis is very difficult [3].

The treatment is exclusively surgical, consisting of resection of the abnormal muscle band and correction of associated cardiac anomalies. It is sometimes necessary to create an atrial septal defect which will serve as an unloading pathway to decrease slightly the preload of the LV which is likely to be maladjusted after the removal of the obstacle, the interatrial communication will then be closed by a percutaneous treatment. Some authors have proposed resorbable banding of the pulmonary artery to allow the LV to adapt gradually to the increased preload [8].

The long-term prognosis of surgical repair of the DCRV is excellent [09] but ¾ of patients have incomplete or complete right bundle branch block in some series [4]. Nevertheless, follow-up is essential to assess the mid- and long-term prognosis. Recurrence of DCRV after surgical correction seems to be rare [9].

## Conclusion

The double chambered right ventricle (DCRV) is a rare congenital malformation, the diagnosis is usually made in infancy or adolescence, very rarely in adulthood, it is often associated with other congenital malformations, the interventricular communication is the most frequent. The treatment is surgical with an excellent long-term prognosis.

**Availability of Data and Materials:** Data sharing is not applicable to this article as no datasets were generated or analyzed during the current study.

**Acknowledgments:** None.

**Conflict of interest:** None.

**Sources of funding:** None.

**Ethical approval:** N/a.

**Consent:** Written informed consent was obtained from the patient for publication of this case report and accompanying images. A copy of the written consent is available for review by the Editor-in-Chief of this journal on request.

## References

1. Cil E, et al. Double-chambered right ventricle: Experience with 52 cases. *International journal of cardiology*. 1995; 50(1): 19-29.
2. Hoffman P, et al. The role of echocardiography in diagnosing double chambered right ventricle in adults. *Heart British Cardiac Society*. 2004; 90(7): 789-93.
3. Romano MM, Furtado RG, Dias CG, Jurca M, Almeida-Filho OC, et al. Double-chambered right ventricle in an adult patient diagnosed by transthoracic echocardiography. *Cardiovasc Ultrasound*. 2007; 5(1): 2.
4. Hachiro Y, Takagi N, Koyanagi T, Morikawa M, Abe T. Repair of double-chambered right ventricle: Surgical results and long-term follow-up. *The Annals of thoracic surgery*. 2001; 72(5): 1520-1522.
5. McElhinney DB, Chatterjee KM, Reddy VM. Double-chambered right ventricle presenting in adulthood. *Ann Thorac Surg*. 2000; 70(1): 124-7.
6. Restivo A, et al. Divided right ventricle: A review of its anatomical varieties. *Pediatric cardiology*. 1984; 5(3): 197-204.
7. Kharwar RB, Dwivedi SK, Sharma A. Double-Chambered Right Ventricle with Ventricular Septal Defect and Subaortic Membrane- Three-Dimensional Echocardiographic Evaluation. *Echocardiography*. 2016; 33(2): 323-327.
8. Park, Joong-Il et al. Isolated double-chambered right ventricle presenting in adulthood. *International journal of cardiology*. 2007; 121(3): e25-7.
9. Amano M, Izumi C, Hayama Y, et al. Surgical Outcomes and Post-operative Prognosis Beyond 10 Years for Double-Chambered Right Ventricle. *Am J Cardiol*. 2015; 116(9): 1431-1435.